

## A NEW SARCOPTID MITE PRODUCING MANGE IN ALBINO GUINEA-PIGS

A. FAIN (1), G.J.R. HOVELL (2) and K.H. HYATT (3)

(Received for publication on 14 July 1972)

During the summer of 1970 a number of cases of mange were observed in a colony of albino guinea-pigs (*Cavia porcellus*) in a laboratory in Oxford. The year before several experimental guinea-pigs from the same colony had been suffering from skin lesions, the cause of which had not been determined using either histological techniques or conventional skin scrapings.

By means of a technique using a 10 % Potassium hydroxide solution, modified and described by WESTON (1970), it was possible to find a few mites in the skin of the animals in the second outbreak. Unfortunately only larvae and nymphs were available for identification purposes as in the meantime treatment of the guinea-pigs with a parasiticide was started, and those worst affected were sacrificed. The mites resembled fairly well *Trixacarus diversus* SELLNICK, a monotypic species described from *Rattus norvegicus*, except in some characters of the chaetotaxy and the dorsal scales which were distinctly different.

No other cases of mange have been observed in this colony of caviae nor any more mites found despite selective culling and examination on several occasions, but in the spring of 1972, mange lesions appeared in another quite separate stock of guinea-pigs in an animal house a few miles away. A careful examination with the technique already used, allowed the recovery of fresh specimens of mites of the same species as that found in 1970, but on this occasion not only were immature forms demonstrated but also several adults of both sexes.

The specimens belong to a new species of Sarcoptidae. The genus to which they are the nearest is *Trixacarus*. However the adult mites are distinguished from the only species known in that genus (*T. diversus*) by several important characters such as the absence of the hysterosomal shield in the female and the absence of the median pregenital sclerite in the male. These differences require the establishment of a new subgenus to contain these mites.

(1): Institut de Médecine Tropicale, Antwerp, Belgium.

(2): University Laboratory of Physiology, Oxford, England.

(3): British Museum (Natural History), London, England.

FAMILY SARCOPTIDAE MURRAY, 1877

Genus *Trixacarus* SELLNICK, 1944

Subgenus *Caviacoptes* subg. nov.

**Definition:** This subgenus is distinguished from the typical subgenus by the following characters:

1. In both sexes the scaly dorsal field extends until the posterior border of the body.
2. The hysterosomal shield is completely absent in the female. There is a strong reduction of this shield in the male.
3. The propodosomal shield is small in the female.
4. Absence or vestigial aspect of median pregenital sclerite in the male.

**Typical species:** *Trixacarus (Caviacoptes) caviae* spec. nov.

*Trixacarus (Caviacoptes) caviae* spec. nov.

**FEMALE** (holotype) (fig. 1-2): Total length (gnathosoma included) 189  $\mu$ , maximum width 144  $\mu$ . **Dorsal surface:** propodosomal shield strongly reduced and poorly sclerotized, approximately 18  $\mu$  long and 18  $\mu$  wide. Dorsum with a spaced striation in the anterior half. The posterior half of the body with a very fine and inconspicuous striation and covered with numerous elongate scales. Anus dorsal. Copulatory papilla long and narrow. **Ventral surface:** epimera I fused in an Y; sternum short. Epimera III loosely connected with epimera IV by means of narrow punctate bands. Gnathosoma as long as wide (30  $\mu$ ) enveloped with membranes. Legs short, as in *Trixacarus diversus*.

**Chaetotaxy,** setae *vi* rather long. Other setae as in *Trixacarus diversus* but shorter and thinner. It is to be noted that in the holotype the pair of pregenital setae (*ga*) are lost and are represented only by their bases. They are present in the paratypes.

**MALE** (allotype) (fig. 3-4): Total length (gnathosoma included) 135  $\mu$ , maximum width 102  $\mu$ . **Dorsal surface:** propodosomal shield more developed than in female, it is about twice as long as wide. In the posterior part of the dorsum there are two small lateral punctate areas very poorly sclerotized. Scaly area similar as in the female. Anus terminal. Dorsal chaetotaxy as in the female but the hairs are weaker. **Ventral surface:** as in *Trixacarus diversus* but the sternum is shorter and the pregenital sclerite is absent or vestigial. Legs and gnathosoma as in *T. diversus*.

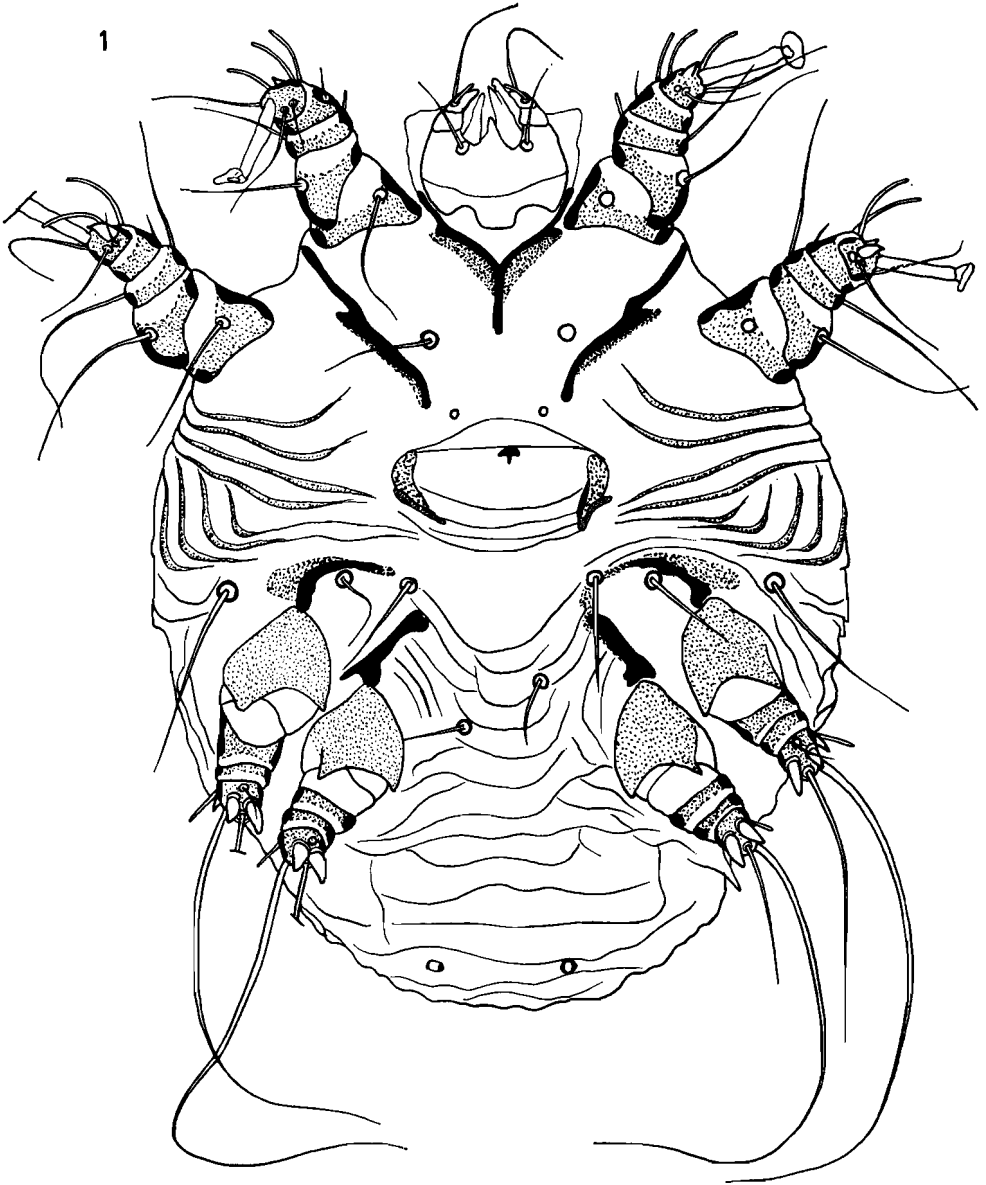


Fig. 1. — *Trixacarus (Caviacoptes) caviae* sp. n.: Holotype female in ventral view.

TRITONYMPH : 171  $\mu$  long and 126  $\mu$  wide. Dorsum as in the female, except that there is no copulatory tube. Venter as in the female but there is no vulva and the epimera III and IV are free.

PROTONYMPH : 141  $\mu$  long and 105  $\mu$  wide. Dorsal scales as in tritonymph but smaller ; the trochantera I, II and III are devoid of setae and the tarsi I bear only one solenidion.

LARVA : 125  $\mu$  long and 93  $\mu$  wide. Dorsum with the same scaly field as in the protonymph. Setae less numerous than in protonymph.

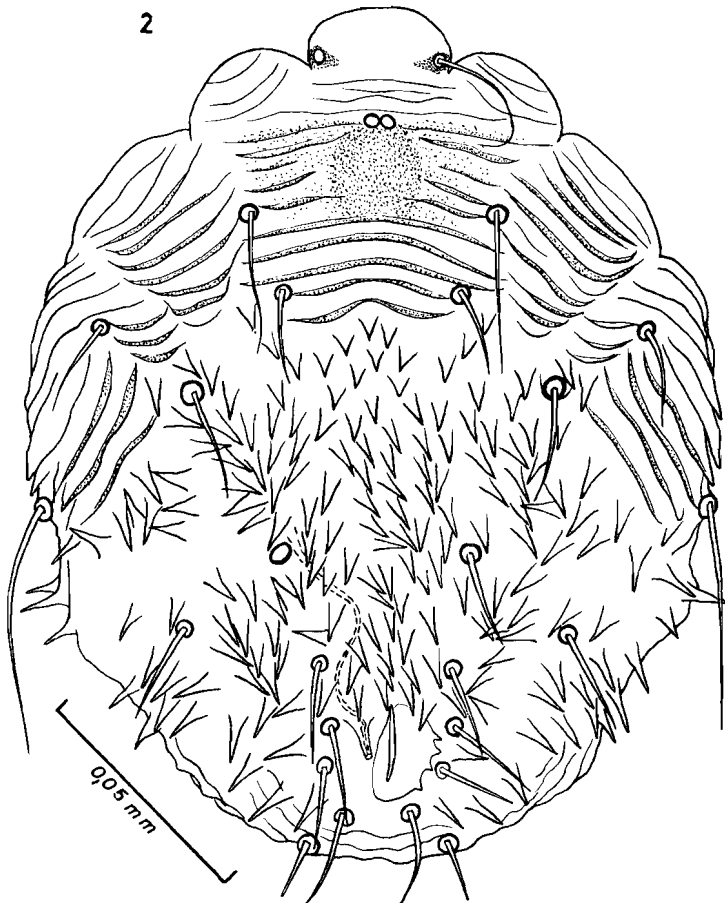


Fig 2. — *Trixacarus (Caviacoptes) caviae* sp. n. : Holotype female in dorsal view.

Host: In mange lesions of albino guinea-pigs (*Cavia porcellus*), in Oxford, England (1970 and 1972). (Holotype and 2 paratypes females; allotype male, several nymphs and larvae paratypes).

Types in the British Museum (Natural History).

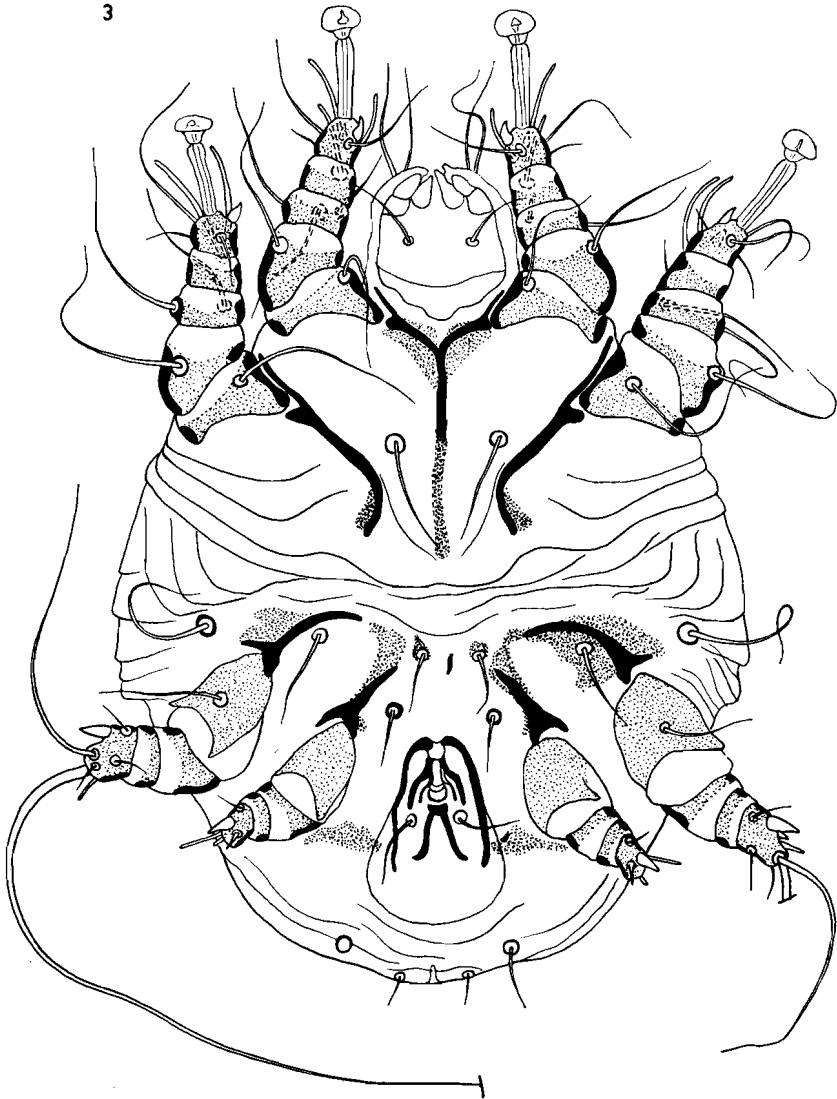


Fig. 3. — *Trixacarus (Caviacoptes) caviae* sp. n.: Allotype male in ventral view.

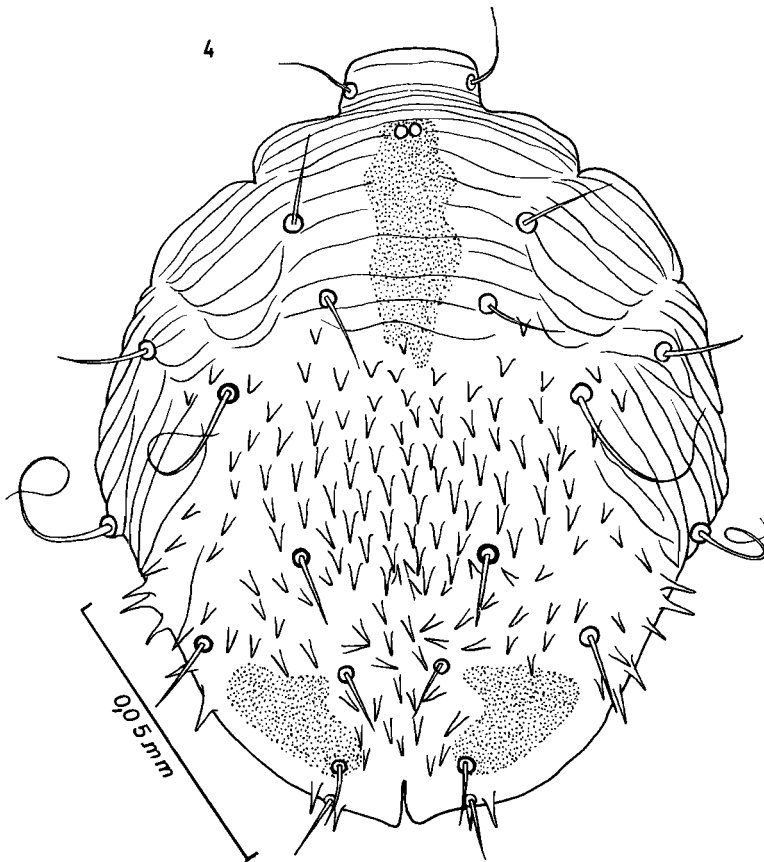


Fig. 4. — *Trixacarus (Caviacoptes) caviae* sp. n.: Allotype male in dorsal view.

#### Description of lesions:

Pathogenesis and clinical signs were similar to those described by SOULSBY (1968) under the general heading of sarcoptic mange. The mites caused irritation and inflammation which was exacerbated through rubbing, biting or scratching by the guinea-pigs. Hair was lost from the affected areas and could be found in the trays under the cages: the skin became thickened and wrinkled and in some cases was infected by secondary bacteria. Areas most frequently parasitized were the lower abdomen extending down the inside of the thighs and axillary regions, which developed lesions in the form of a red rash initially, and the neck and shoulder parts, which were particularly prone to damage inflicted by the

hind feet. The ears and face of a typical case did not appear to be involved nor were the feet or lower legs noticeably, but all parts of the body were affected in a few guinea-pigs with extensive lesions. In the most recent outbreak about one third of the population, totalling 250, was clinically affected — many of the pregnant sows were amongst those itching most severely. It was estimated that on one average pelt there were 50 mites of all ages.

#### Predisposing Factors

In both stocks of guinea-pigs there were factors causing stress, operating at the time of the outbreaks. Apart from pregnancy and experimental treatments, those factors thought to predispose to clinical manifestations of mange were, in one case, environmental temperatures in excess of those tolerated well by guinea-pigs and, in the other instance, sub-optimal ventilation and a degree of overcrowding. The beneficial response to bathing the animals in a parasiticide solution of Tetraethylthiuram monosulphide \* was striking and attention was also given to improving ventilation and stocking density: at the same time a supplement of green food was given to hasten recovery and re-establish positive health.

The possibility exists that the guinea-pig is an unusual host for this species of mite as apart from the fact that these mites live and breed on this animal there is not conclusive evidence that it is the usual host.

#### ACKNOWLEDGEMENTS

We are grateful to the Public Health Laboratory, Oxford, and the Nuffield Institute for Medical Research, Oxford, for cooperation in the investigation of the problems, and to R. WESTON for his technical skill and persistence in demonstrating the presence of the mites.

#### SUMMARY

The authors describe a new species representing a new subgenus of a sarcoptid mite producing mange in albino guinea-pigs in a laboratory in Oxford, England.

---

\* Tetmosol. I.C.I.

The lesions consisted in irritation and inflammation, with thickening of the skin and loss of hair. They were located mainly along the sides of the abdomen, the neck and the shoulders. The ears and the face were generally not involved nor were the feet or lower legs noticeably.

### SAMENVATTING

De auteurs beschrijven een nieuwe soort en een nieuw subgenus van de familie Sarcoptidae. Deze mijt had kleine schurft epizooties veroorzaakt in een kweekerij van albinos cavia's in een laboratorium van Oxford, Engeland.

De letsels bestonden uit prikkeling en ontsteking met verdikking van de huid en depilatie, bijzonder langs de schouders en de flank. De poten waren in mindere mate aangetast. Bij de meeste dieren waren er geen letsels aan de oren en het aangezicht.

### R E S U M E

Les auteurs décrivent une nouvelle espèce et un nouveau sous-genre d'acariens de la famille Sarcoptidae. Cet acarien était responsable de petites epizooties de gale dans un élevage de cobayes albinos, dans un laboratoire d'Oxford, Angleterre.

Les lésions consistaient en irritation et inflammation avec épaissement de la peau et perte de poils. Elles étaient localisées principalement le long des flancs, dans le cou et sur les épaules. Les oreilles et la face n'étaient généralement pas atteintes. Les pieds et les extrémités des pattes n'étaient que légèrement touchés.

### ZUSAMMENFASSUNG

Die Verfasser beschreiben eine neue Art und eine neue Gattung der Familie Sarcoptidae. Die Milben hatten in einem Laboratorium in Oxford, England, kleine Epizootien von Krätze in einer Züchtung von Albino-Meerschweinchen verursacht.

Die Wunden bestehen aus Entzündungen mit Verdickung der Haut und Enthaarung, hauptsächlich an der Schulter und der Seite. Die Pfoten waren wenig befallen. Bei den meisten Tieren waren keine Wunden an Kopf.



## REFERENCES

- FAIN, A. (1968) : Etude de la variabilité de *Sarcoptes scabiei* avec une révision des Sarcoptidae. *Avta Zool. Pathol. Antverp.* 47, 1-196.
- SELLNICK, M. (1944) : Eine neue parasitische Milbe von *Epimys norvegicus* ERXL. *Z. f. Parasitenk.* 13 ; 248-253.
- SOULSBY, E.J.L. (1968) : *In Helminths, Arthropods and Protozoa of Domesticated Animals* (Monnig), 6th ed., p. 505, Balliere, Tindall & Cassell : Londen.
- WESTON, R.W. (1970) : *Bull. Institute Science Technology.* 16. 4, p. 4.